



Case Studies

Case Numbers | 102, 105, 111, 113, 121, AJ-GW 1, AOP-GW1, AOP-GW2, AOP-GW3, AOP-GW4, 1187034

January 2024



Case Study #102

Patient

38 yr old female

Diagnosis

SCI (Paraplegia)

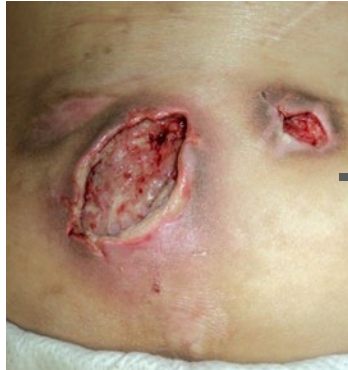Condition

Sacral decubitus ulcer

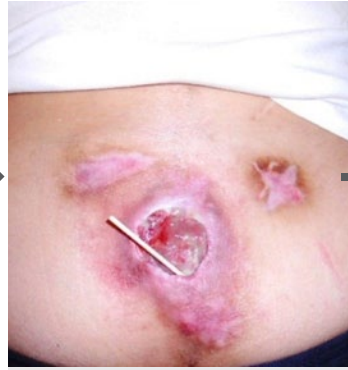Frequent movement while sitting, shifting and repositioning.

16 months of wound therapy, slow progress

Case study report courtesy of:
Jan Chevrette, MSN, FNP-C, RN
Regions Hospital
St. Paul, MN



AUG 19 | 2010



APRIL 4 | 2011



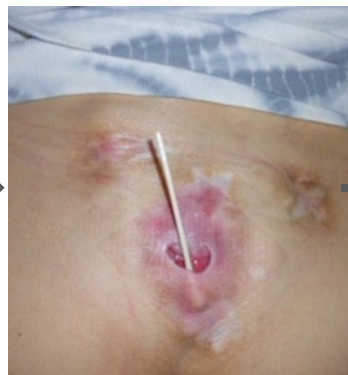APRIL 6 | 2011

GlideWear back drape on w/c backrest installed; Wound therapy continues



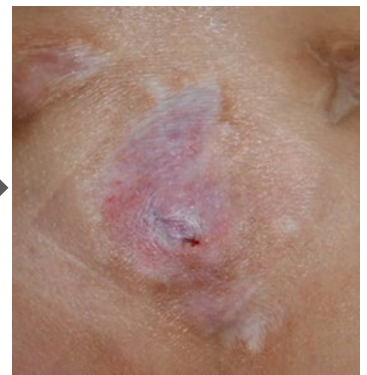
JULY 15 | 2011

Wheelchair backrest cover with GlideWear; seat cushion with GlideWear added. Wound therapy and healing continue



AUG 16 | 2012


Wound therapy and healing continues



OCT 22 | 2013

Wound nearly healed 4 yrs 9 months total. Significant healing improvements occurred within the 2 years and 5 months using GlideWear.

Scan to learn more about
GlideWear® from Tamarack®



[CLICK TO LEARN MORE](#)

Case Study #105

Patient

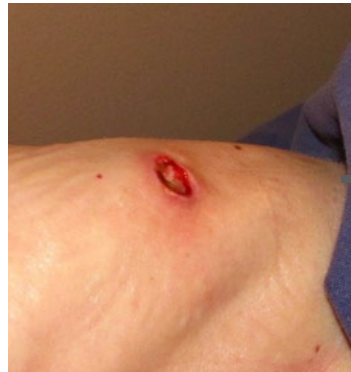49 yr old female

Diagnosis

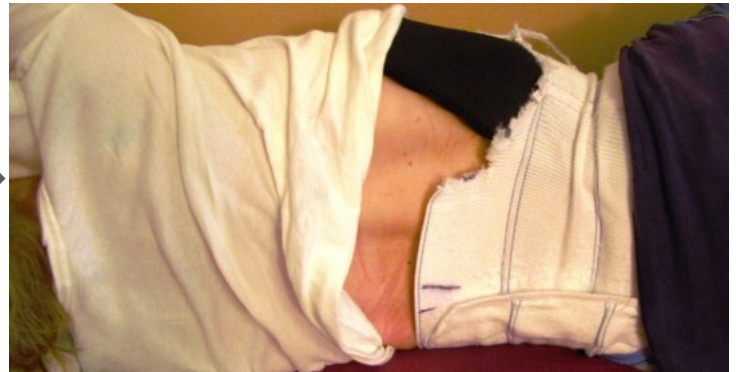SCI (Quadriplegia)

Condition

Decubitus ulcer, stage III caused by orthotic corrective pad at right thorax.




AUG 23 | 2012

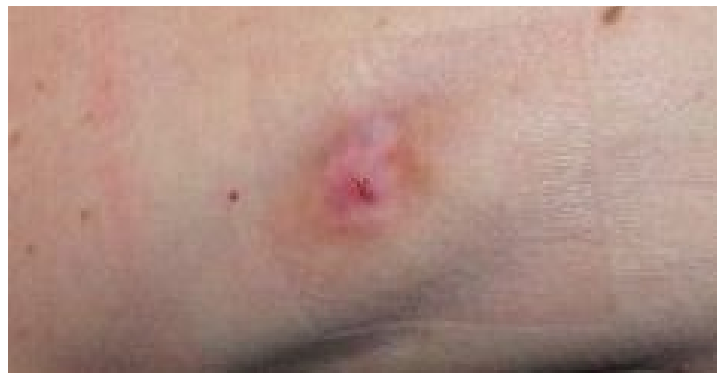

AUG 28 | 2012

After 5 months of wound therapy w/o significant result. GlideWear insert added to standard therapy.



GlideWear insert




OCT 15 | 2012

Wound healed within 2 months following addition of GlideWear to standard wound therapy. Use continues prophylactically - skin remains intact 11 months post healing (Nov 13)

Case study report courtesy of:
Self-referral under professional care of
Julie Roskamp, RN, CWCON
Twin Cities Wound and Ostomy
Associates Inc.
Lakeville, MN, USA

Scan to learn more about
GlideWear® from Tamarack®



[CLICK TO LEARN MORE](#)

Case Study #111

Patient

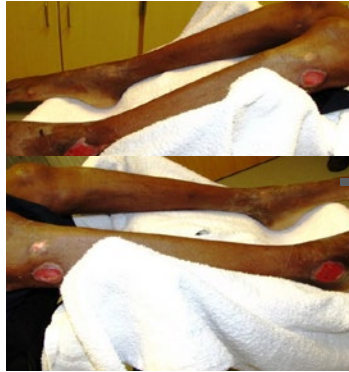37 yr old male

Diagnosis

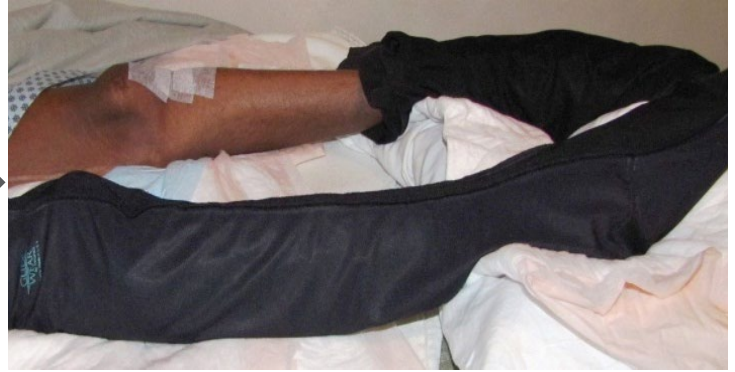SCI (Quadriplegia)

Condition

Multitude of decubitus ulcers stage III at the lower extremities caused by night time bed positioning.



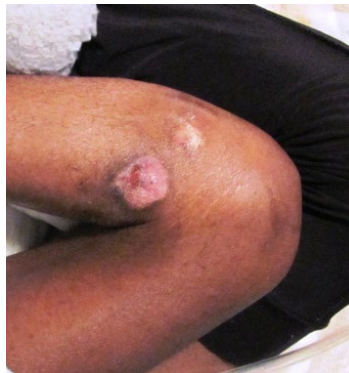FEB 25 | 2013



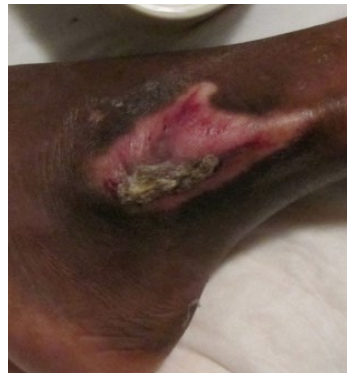APR 9 | 2013

Patient receives two long-leg GlideWear stockings and begins to apply these while laying in bed..

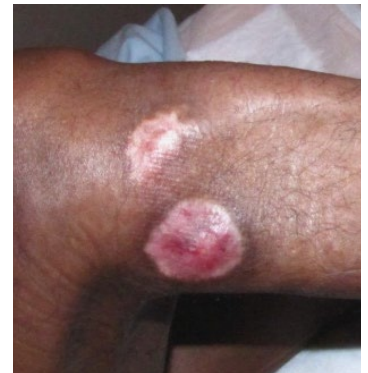Wound therapy continues.



OCT 31 | 2013



OCT 31 | 2013

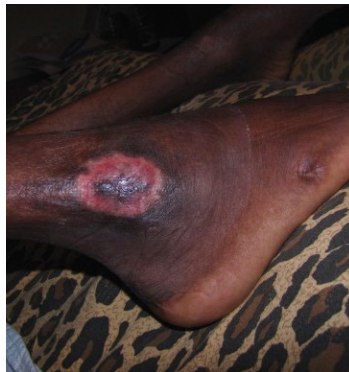


OCT 31 | 2013

Wounds malleolus rt. and both knees are healed. Lateral malleolus lft. healed at 85%. Treatment to be continued for preventative and therapeutic reasons.

Case study report courtesy of:
Adam Reed Johnson, DPM
Medical Director
Center for Wound Healing
Hennepin County Medical Center
Minneapolis, MN 55415

Scan to learn more about
GlideWear® from Tamarack®



OCT 31 | 2013

[CLICK TO LEARN MORE](#)

Case Study #113

Patient

Geriatric Male

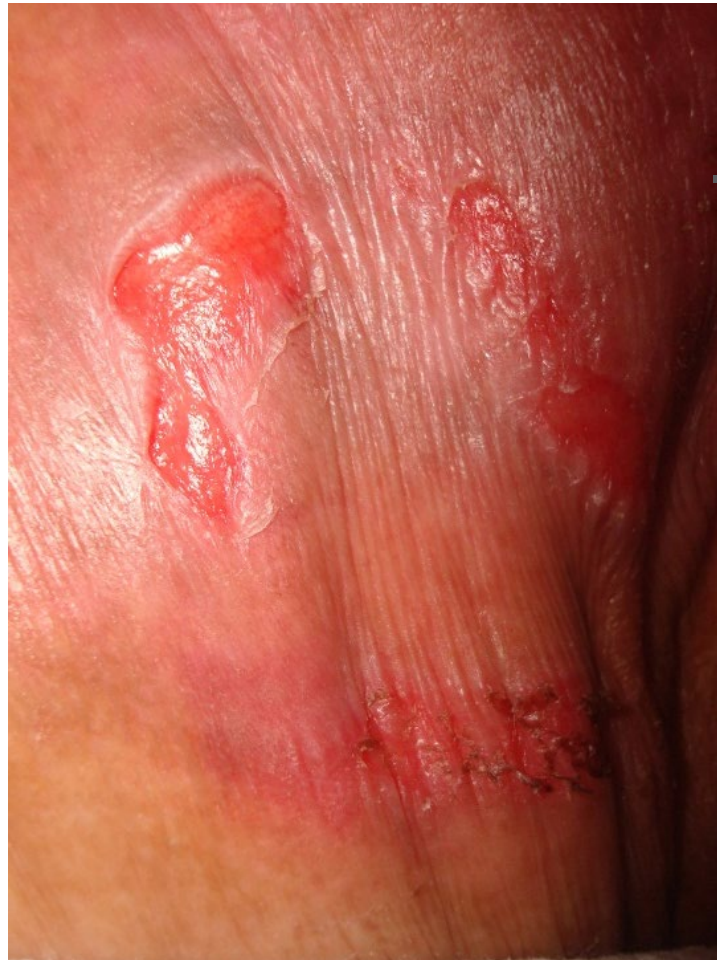Diagnosis

Immobile, bed bound,
recent CVA slow progress

Condition

Sacral/gluteal decubitus ulcer
stage II

Case study report courtesy of:
Rosie Jovane, CPO
Distance treatment;
Patient lives in Panama.

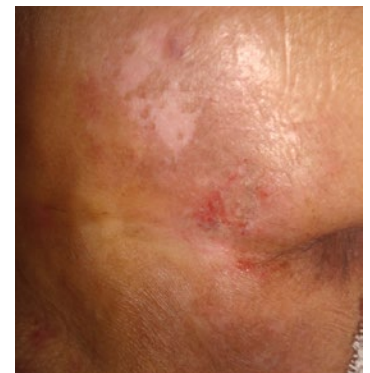

JUN 19 | 2013



JUN 19 | 2013


Standard medical wound care provided.
Pt. receives custom modified boxer brief
with posterior GlideWear panel. Begin of
regular application on 07/24.



OCT 10 | 2013

Patient still bed-bound.
Wound healed after 3.6 months of
continuous GlideWear garment
application.

Scan to learn more about
GlideWear® from Tamarack®



[CLICK TO LEARN MORE](#)

Case Study #121

Patient

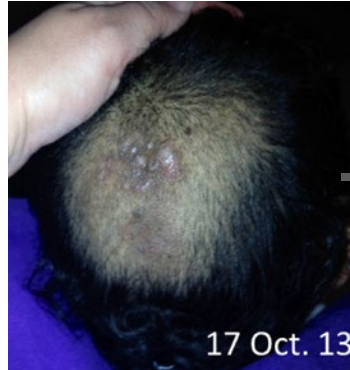14 yr old female

Diagnosis

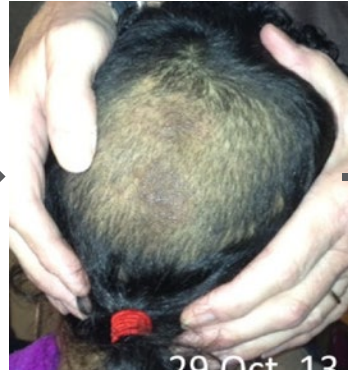Athetoid Cerebral Palsy

Condition

Inflammation, callus and blistering formation on back of head. Severe hair loss.

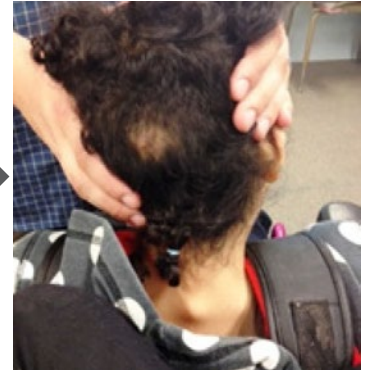


OCT 17 | 2013



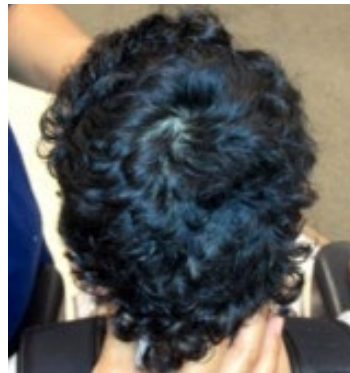
OCT 29 | 2013

Application of GlideWear on wheelchair headrest, bed cover, and pillowcase. Inflammation and blistering resolved. Hair is growing again
(GlideWear in use for 6 days)



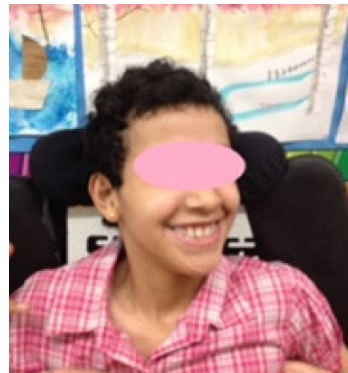JUN 10 | 2014

Student still using the GlideWear- covered headrest. Small spot with reduced hair growth remaining.




AUG 25 | 2014

Hair problem resolved



Case study report courtesy of:
Chris Cantu, OTR/L
School Therapist and with family permission

Scan to learn more about
GlideWear® from Tamarack®



[CLICK TO LEARN MORE](#)

Case Study
#AJ-GW 1

Patient

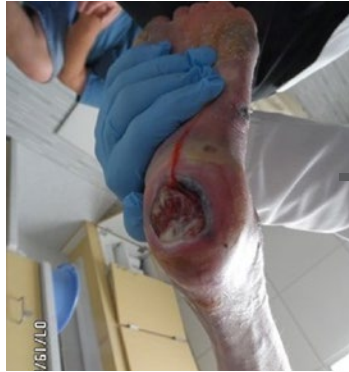50 yr old female

Diagnosis

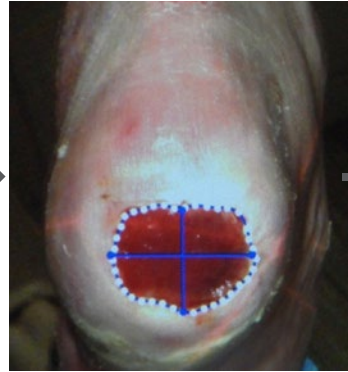
Spinocerebellar Ataxia

Condition

Decubitus ulcer, left heel, stage II.

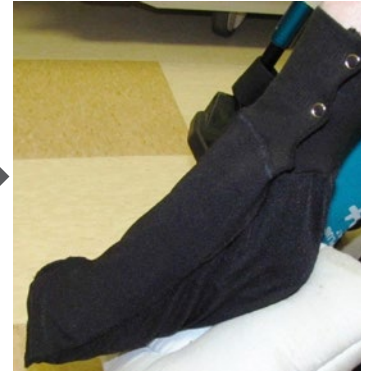


JULY 19 | 2013



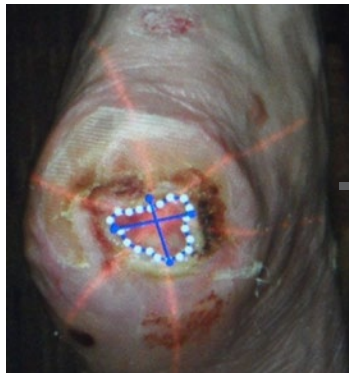AUG 2 | 2013

Referred for pot. amputation. Started on cultured fibroblasts (Dermagraft).



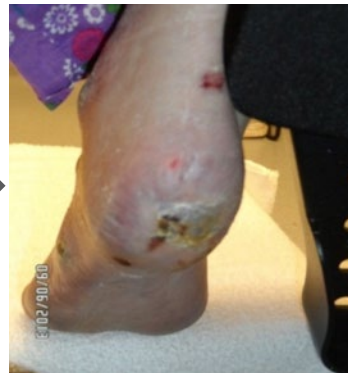AUG 12 | 2013

Received GlideWear Therapy Sock



AUG 24 | 2013

Wound 50 % reduced




SEPT 13 | 2013

Wound healed

Case study report courtesy of:
Adam Reed Johnson, DPM
Medical Director Center for Wound Healing
Hennepin County Medical Center
Minneapolis, MN 55415

Scan to learn more about
GlideWear® from Tamarack®



[CLICK TO LEARN MORE](#)

Case Study
#AOP-GW1

Patient

50 yr old female

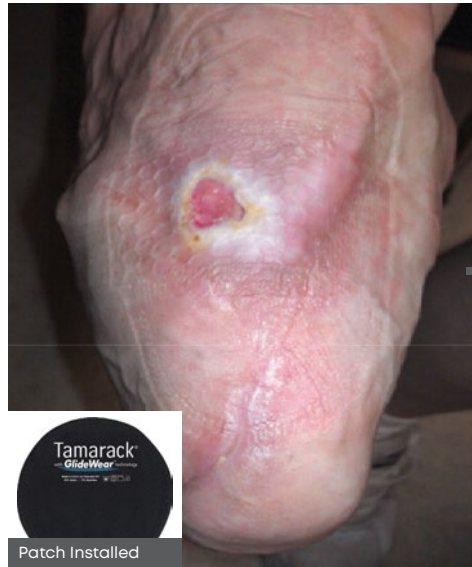
Diagnosis

Traumatic amputation from MVA

Condition

Below knee amputee

Decubitus ulcer, stage II, infected, liner with suction suspension.

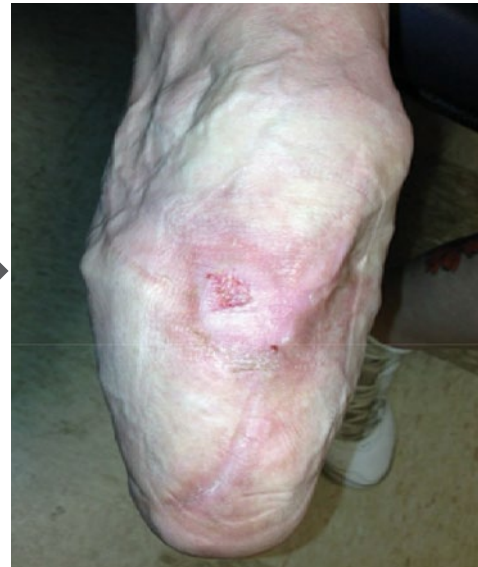

JUNE | 2013

Patient presents with open sore (now open 6 months) deeper and larger than office visit 2 months prior.

On her feet watching grandchildren 10 hours per day.

Wound is infected. Patient to begin using GlideWear daily.



JULY | 2013

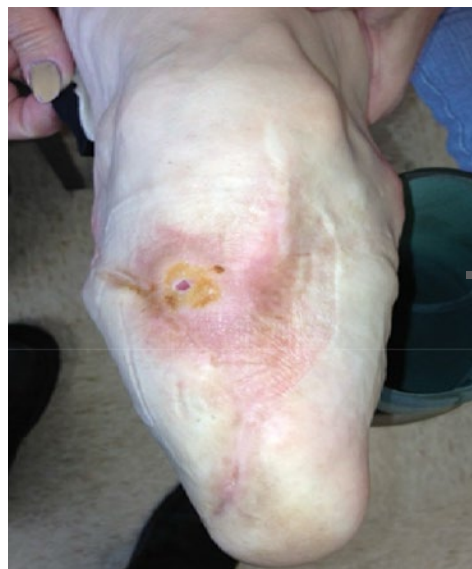
Wound is smaller. She has been on antibiotics.

Infection appears to be resolved. Still wearing prosthetic leg full-time and watching grandchildren.

Wearing GlideWear patch full time.

Case study report courtesy of:
Arise Orthotics & Prosthetics
Blaine, MN USA

Scan to learn more about
GlideWear® from Tamarack®



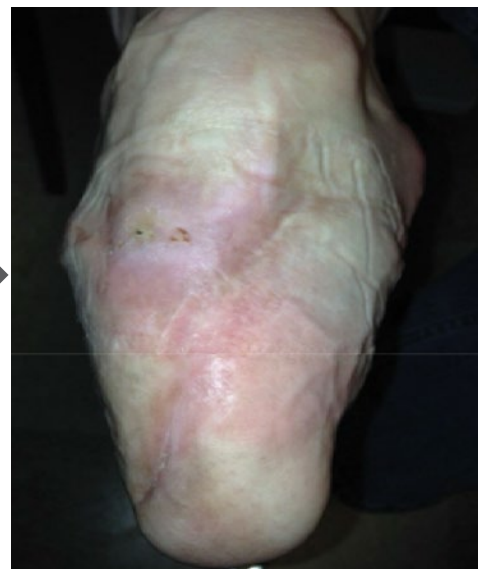SEPT | 2013

Wound is almost healed.

Color of skin is improving and no infection apparent.

Full time use of prosthesis and patient continues all activities.

Wearing GlideWear patch full time.



OCT | 2013

Wound healed.

She will continue use of GlideWear patch full time to prevent shear forces over the previous wound area.

CLICK TO LEARN MORE

Case Study
#AOP-GW2

Patient

57 yr old male

Diagnosis

Diabetic with charcot bony changes in opposite foot

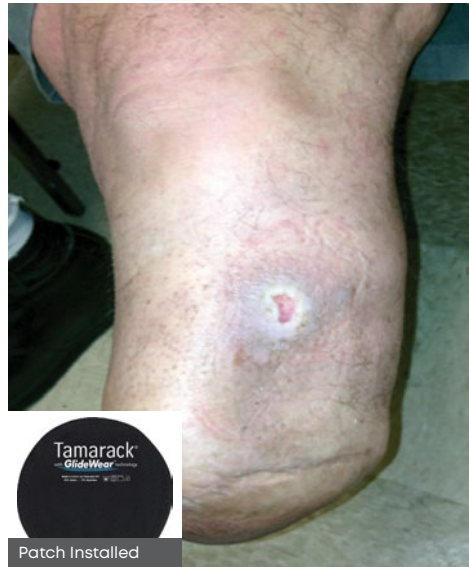
Condition

Below knee amputee

Decubitus ulcer, stage I

Gel locking liner with pin suspension

Patient is employed and is on his leg actively 14+ hours a day

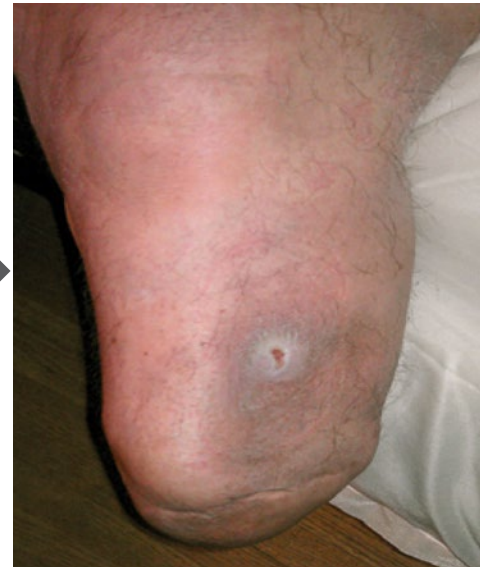

AUG 16 | 2013

Patient presents with open wound for the last 2-3 weeks.

Inspection of gel liner shows distal umbrella has torn out and patient is pistoning due to liner failure, wound is from movement in socket and lack of suspension.

Patient is placed in a casting liner with GlideWear patches to start daily use of patches. Replacement liner is ordered.

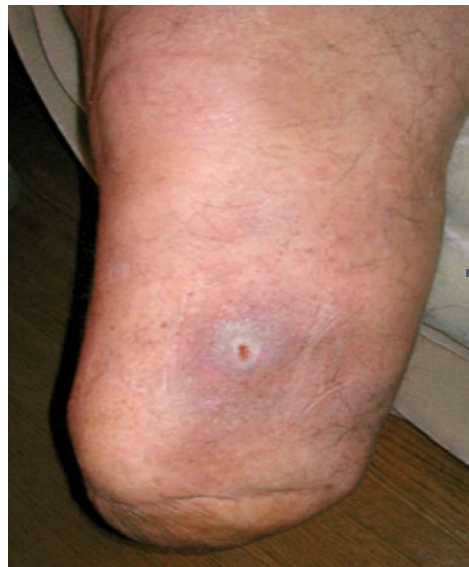

SEPT 3 | 2013

Proper suspension in prosthesis and the use of the GlideWear patches have reduced the wound size by over 50 percent.

Patient is continuing full time use of his prosthesis while the wound is healing.

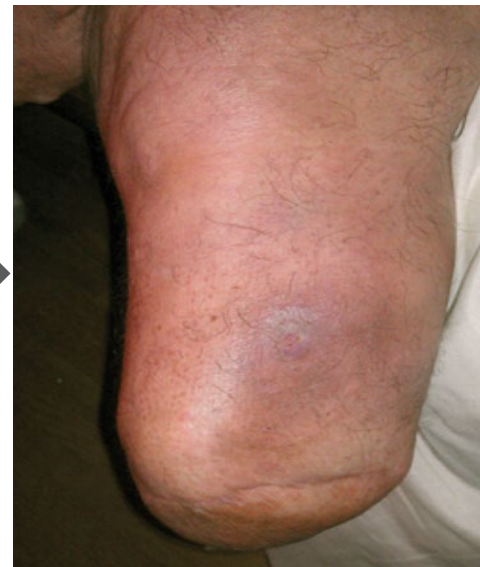
GlideWear patch is being worn full time.



SEPT 11 | 2013

Wound continues to improve. Reduction in size and depth of wound by over 50 percent. Patient continues full time use of his prosthesis and all activities.

GlideWear patches being worn full time.




SEPT 24 | 2013

Wound area is completely healed.

Patient will continue use of GlideWear patch in the area over the next couple of weeks to prevent shear over the previous wound area.

Scan to learn more about
GlideWear® from Tamarack®



[CLICK TO LEARN MORE](#)

**Case Study
#AOP-GW3**

Patient

70 yr old male

Diagnosis

Diabetic with charcot changes on opposite foot

Condition


Below knee amputee

Decubitus ulcer, stage II

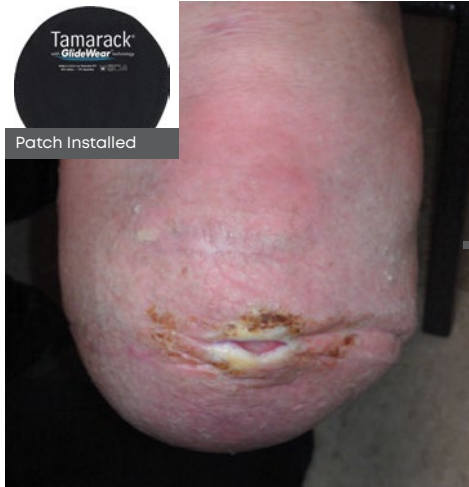Gel locking liner with pin suspension

Case study report courtesy of:
Arise Orthotics & Prosthetics
Blaine, MN USA

Scan to learn more about
GlideWear® from Tamarack®



[CLICK TO LEARN MORE](#)

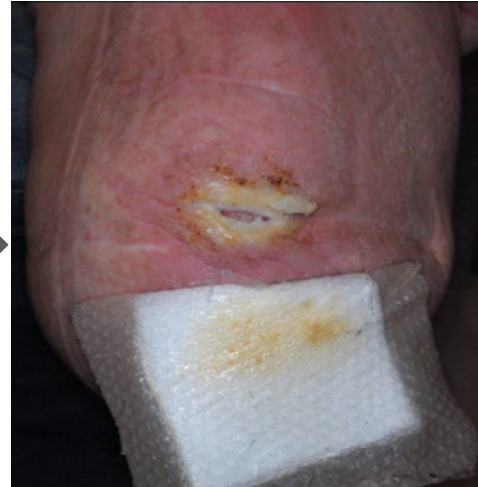

MARCH 22 | 2013

Patient presents with open wound for the last month.

Inspection of limb and socket shows inadequate sock ply with patient bottoming out in his socket.

Pads are placed in anterior socket and proper sock ply is established with patient. GlideWear patches are placed in gel in for full time use. Patient is retired, but still is active around his home.

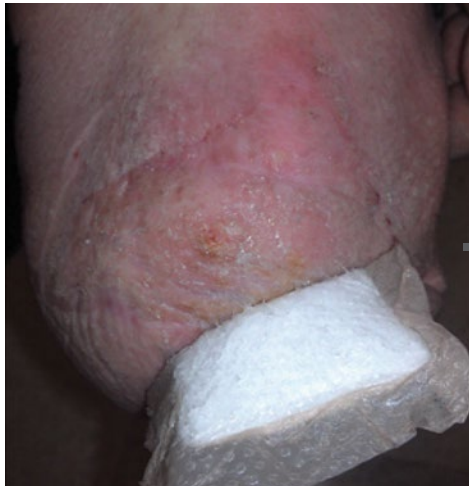

MARCH 28 | 2013

Wound area is smaller.

Patient is using dressings over the wound area along with GlideWear to shearing forces on the distal tibia.

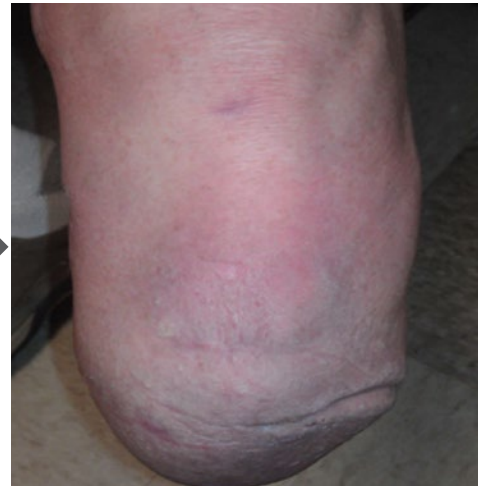Patient is using GlideWear patch full time in prosthesis.



APRIL 23 | 2013

Wound area is completely healed.

Patient to continue use of GlideWear patch full time to reduce shear forces over the previous wound area.



6 WEEKS POST HEALING

Patient remains completely healed and has discontinued use of the GlideWear patches.

Case Study
#AOP-GW4

Patient

34 yr old, 6'4", 280lb, active male

Diagnosis

Right side medial knee compartment osteoarthritis


Condition

Patient is wearing a custom knee brace to unload his medial compartment

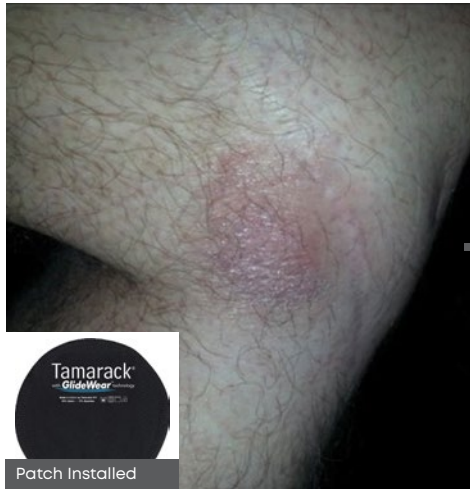Knee pain rated at 8 out of 10 out of the knee brace

Case study report courtesy of:
Arise Orthotics & Prosthetics
Blaine, MN USA

Scan to learn more about
GlideWear® from Tamarack®



CLICK TO LEARN MORE



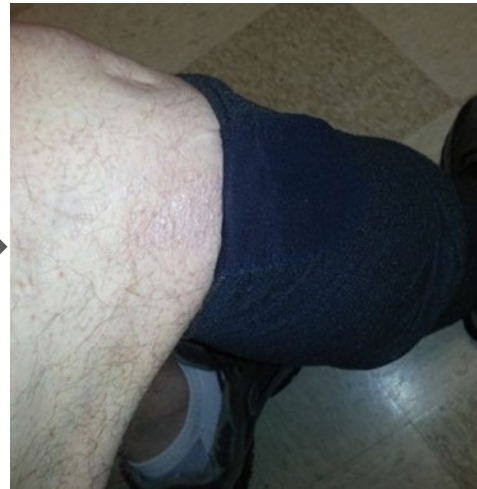JAN 7 | 2013

Patient presents wearing his knee brace with traumatic changes to his skin over the lateral condyle from the corrective forces of the knee brace.

Fit of orthosis is correct and being placed correctly.

GlideWear patch is placed over the lateral condylar pad of the knee brace to reduce the shear forces being placed on his knee while ambulating in the knee brace.

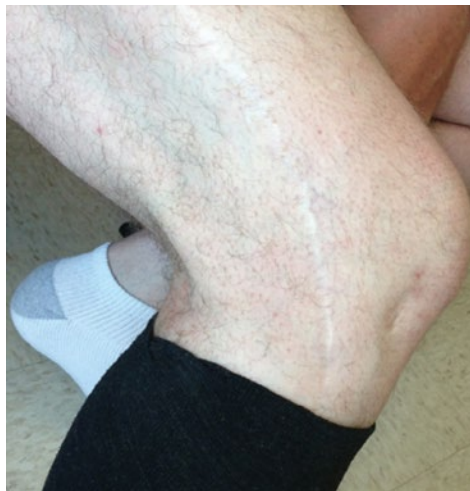GlideWear patch worn full time.



FEB 28 | 2013

Patient has been using the GlideWear patch full time between his skin and an under sleeve for the knee brace.

Patient able to continue full time use of his OA knee brace and skin irritation is improved by over 50 percent. Patient continue full time use of GlideWear patch.



AUG 15 | 2013

Area of concern is completely resolved.

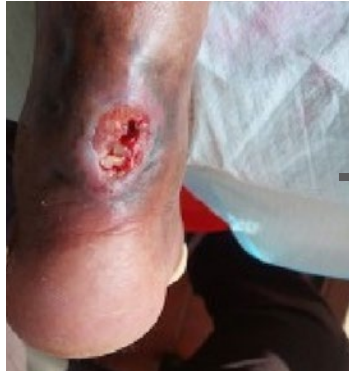Patient has discontinued use of GlideWear patches.

Case Study #1187034

Patient
46 yr old male

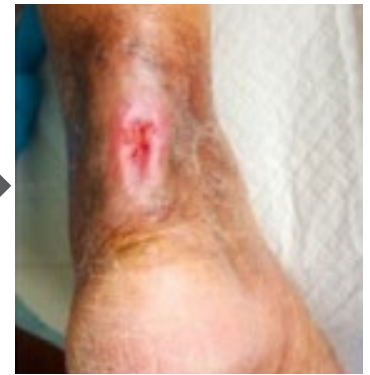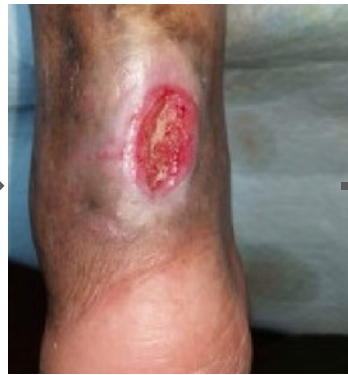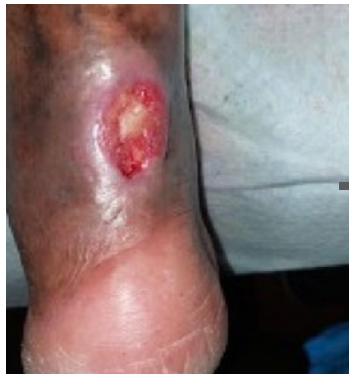Diagnosis
Unknown

Condition
Decubitus ulcer, stage III



JAN | 2023

Case study report courtesy of:
Luis Rodil Peralta, BOCPD
Hospital y Unidad de Pie Diabetico
Lomas Altas, Guatemala

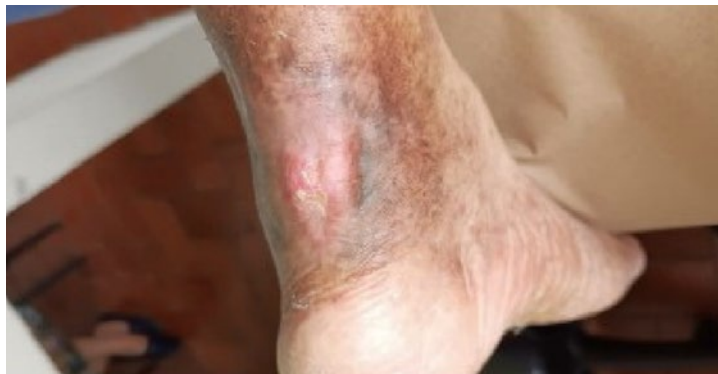


JAN | 2023

JAN | 2023

JAN | 2023

Scan to learn more about
GlideWear® from Tamarack®



AUG | 2023

Ulcer treated for 8 months with a Tamarack Protection Sock with
GlideWear technology is completely healed.

[CLICK TO LEARN MORE](#)